



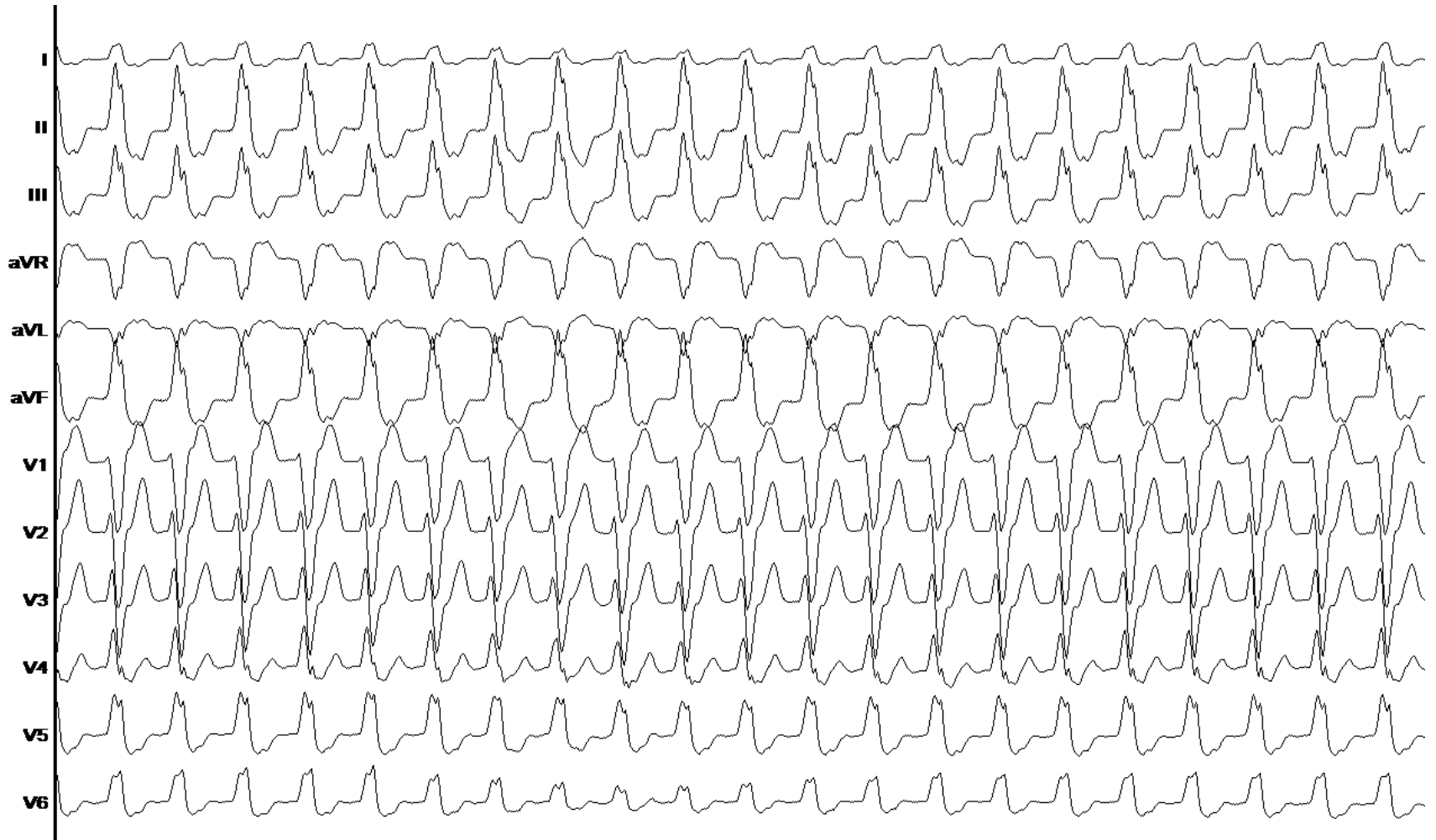
ASSOCIATION DE RYTHMOLOGIE
INTERVENTIONNELLE & STIMULATION

Tachycardie ventriculaire de Gallavardin

Dr Durand

Novembre 2019 – Infirmierie Protestante

ECG initial



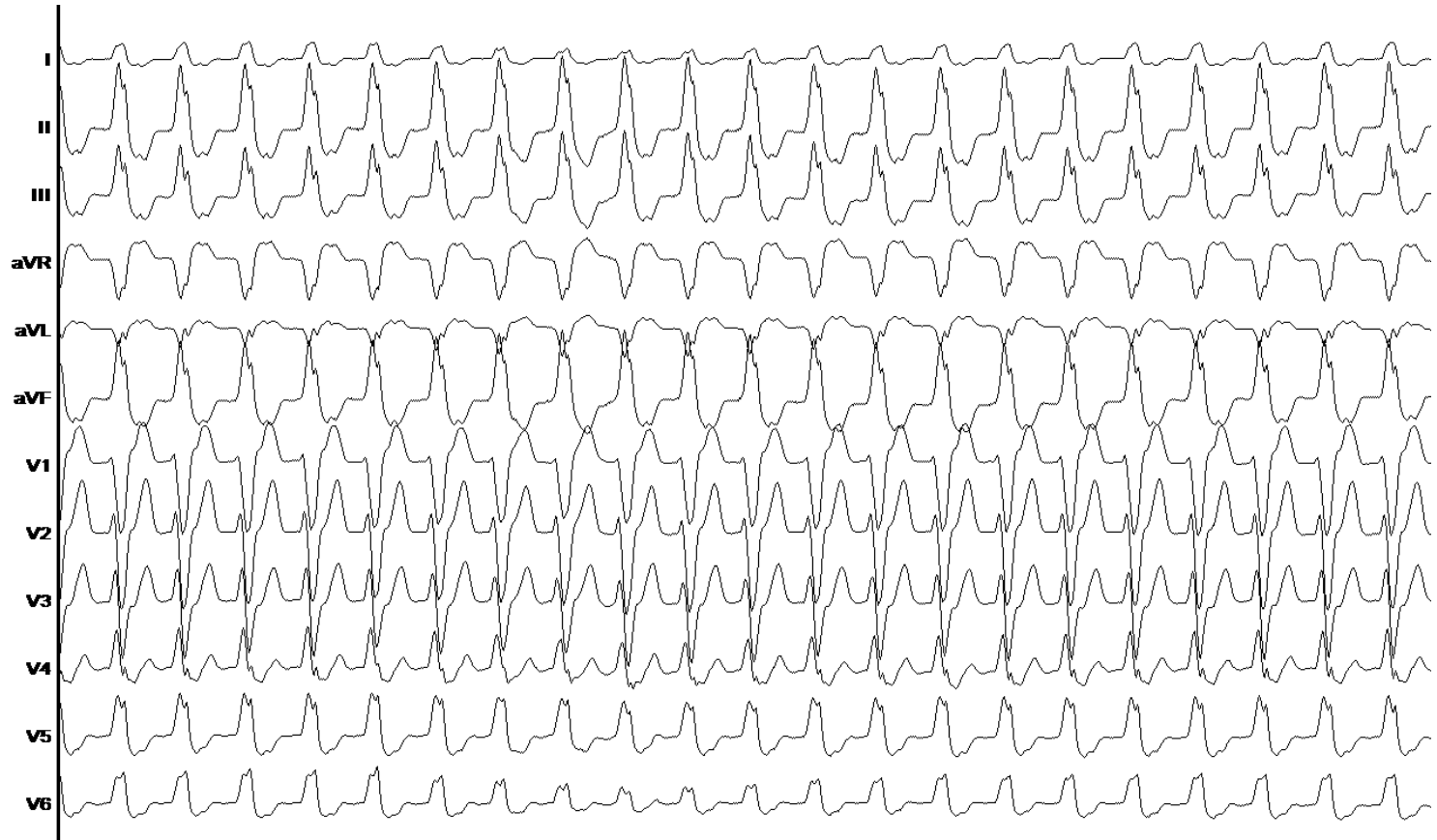
ECG initial

Cadran droit supérieur :

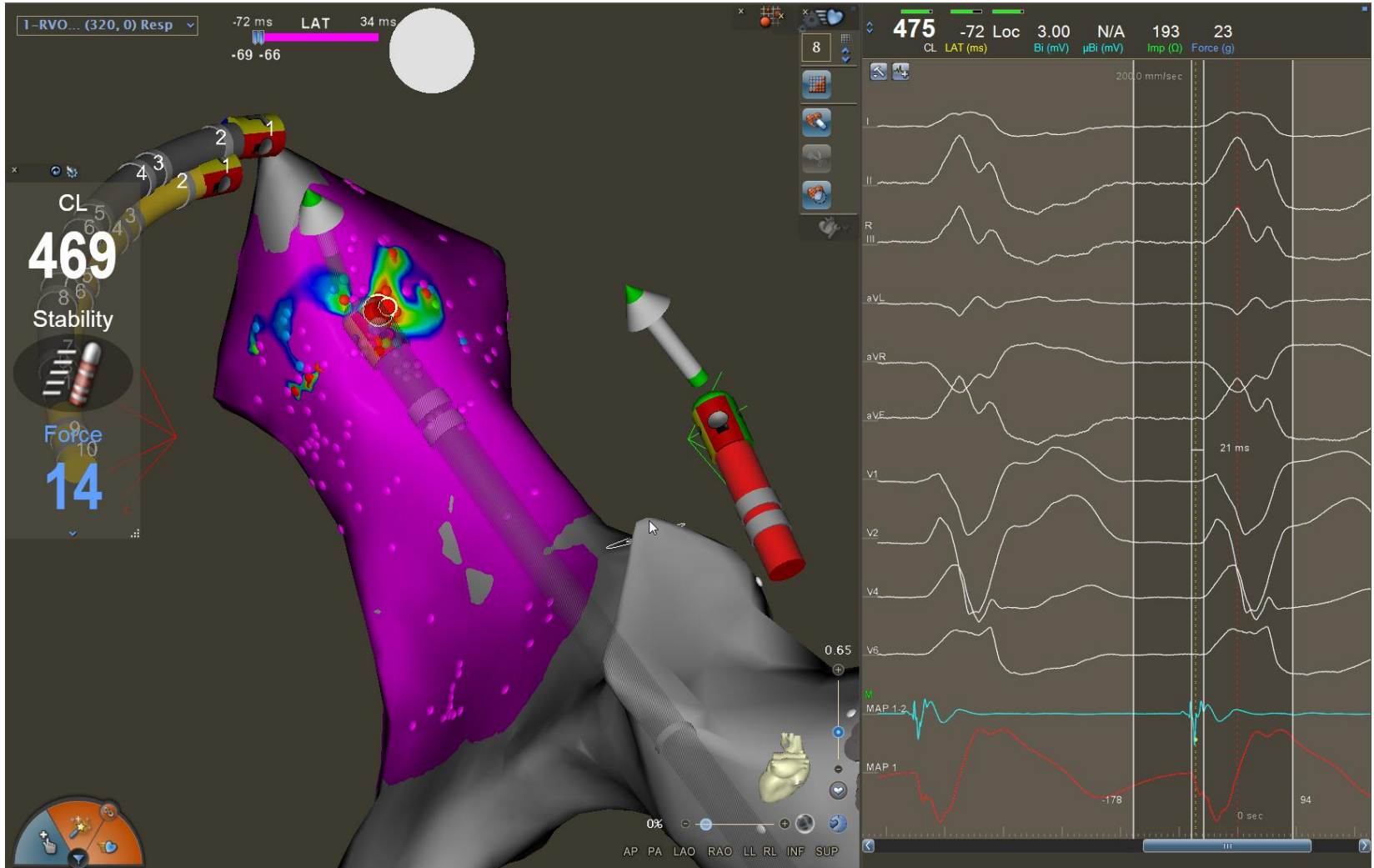
- DII + et DIII +
- DI +

Chambre de chasse droite postérieure:

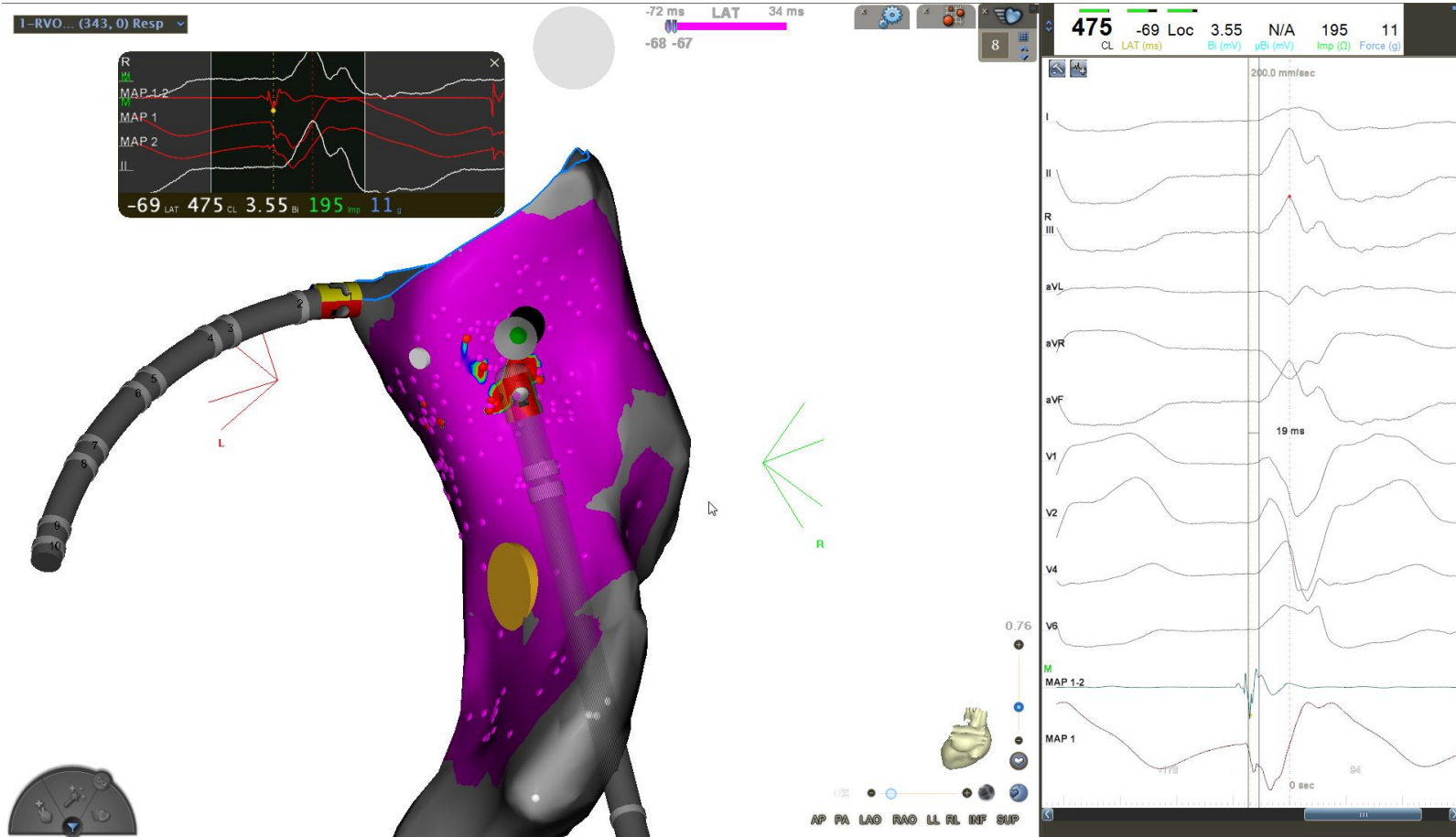
- aVL -
- Transition après V3



Carte d'activation

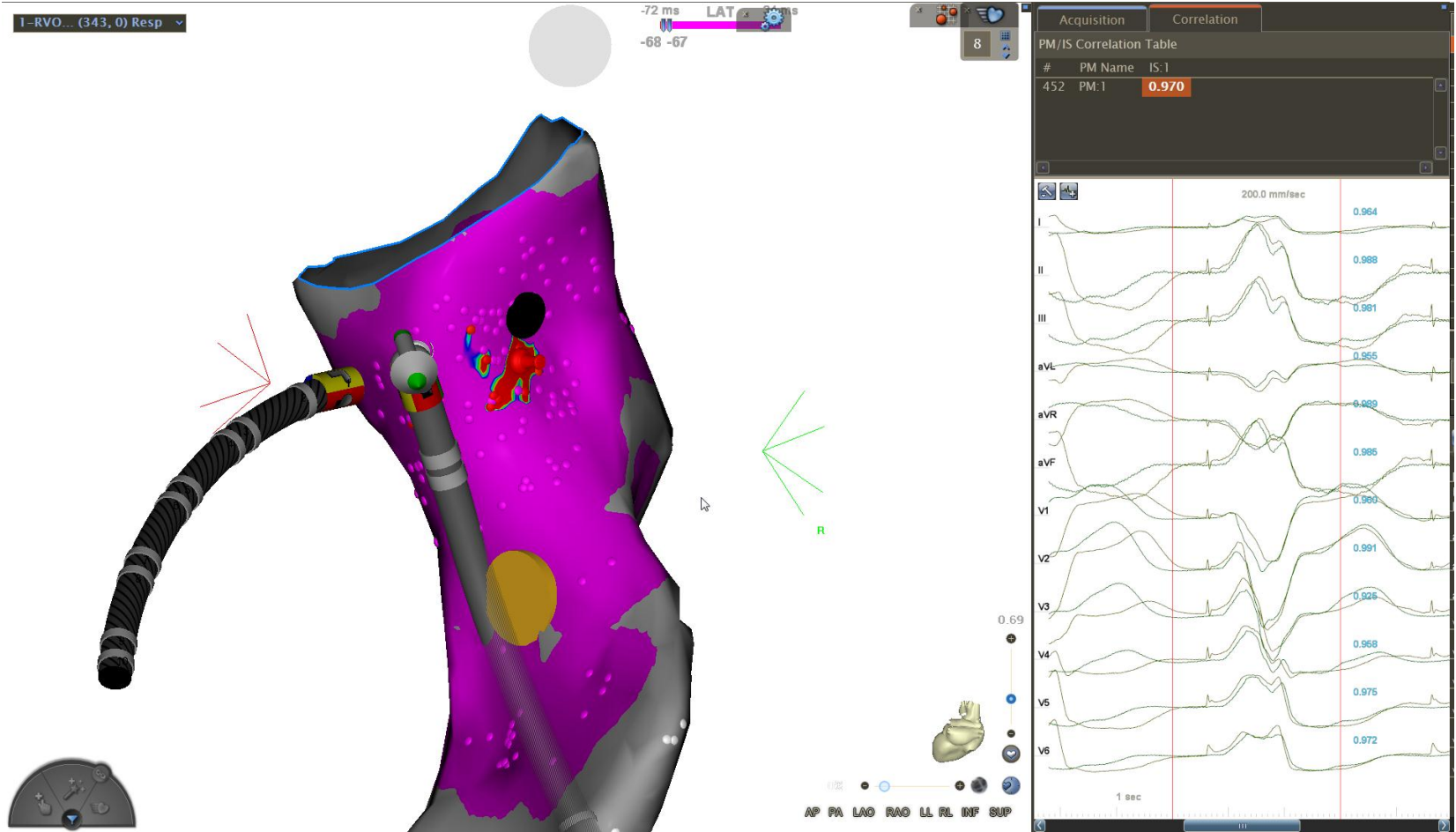


Carte d'activation



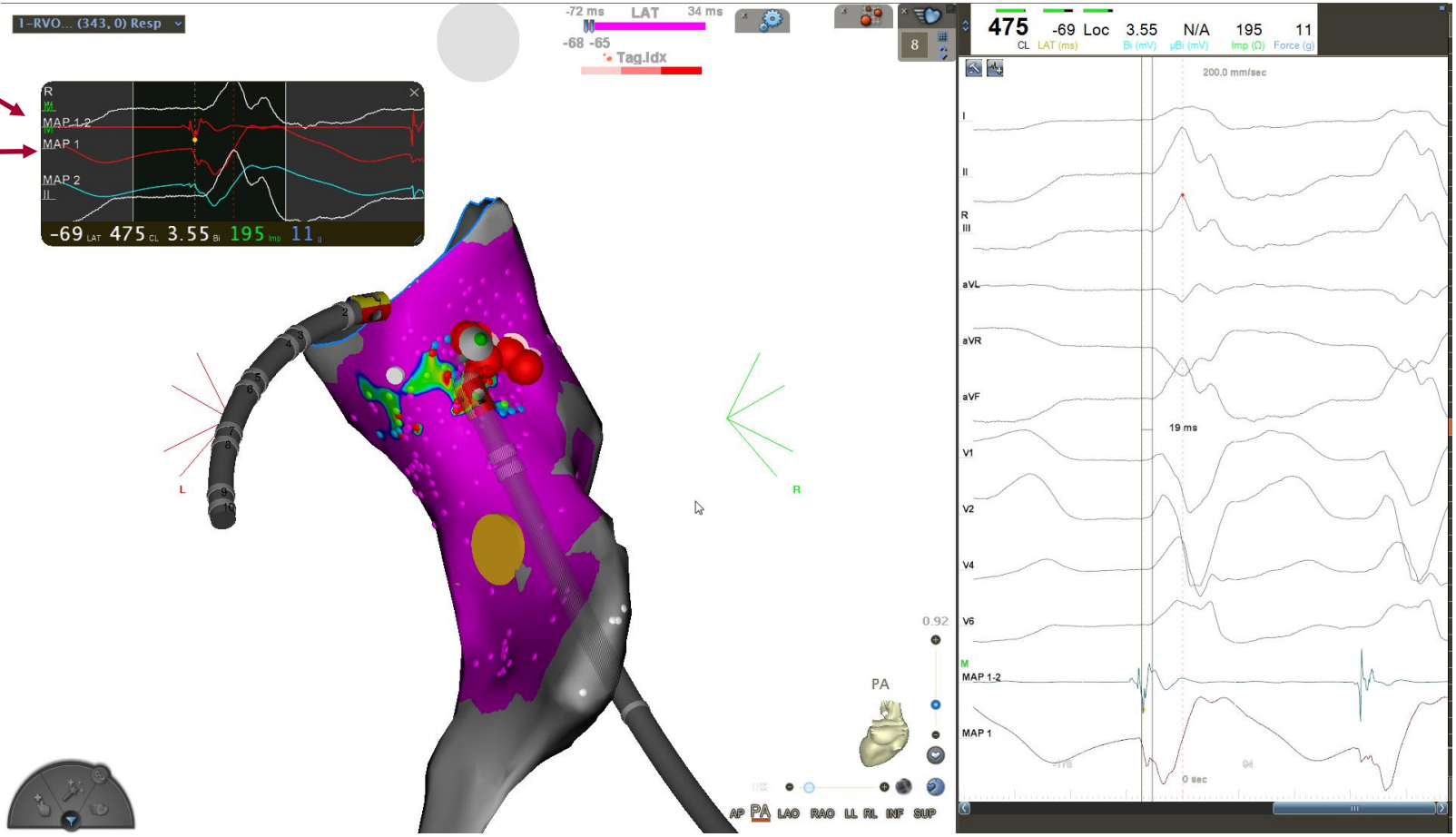
Précocité
19 ms

Pace-mapping

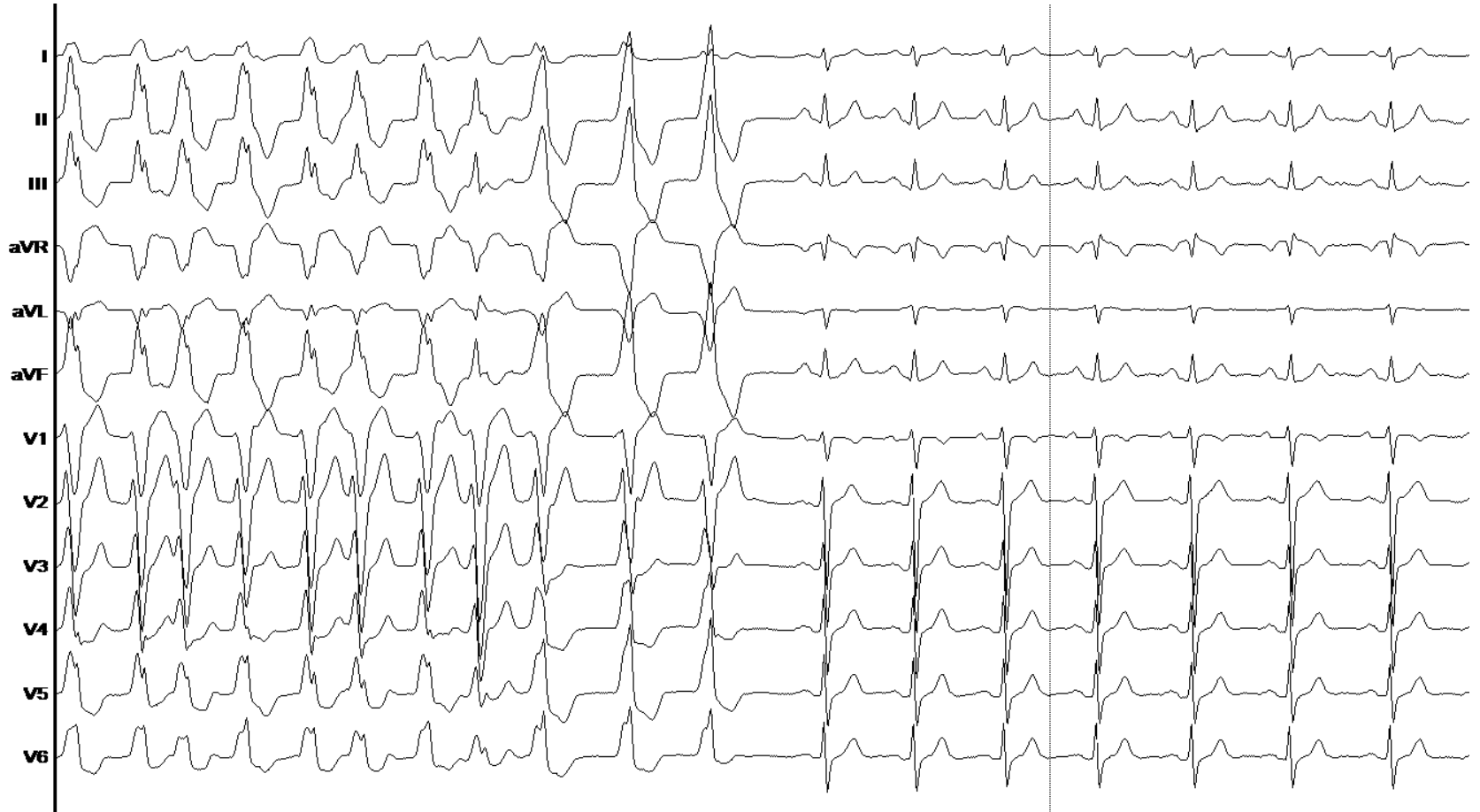


Ablation

Précocité
Unipolaire



Ablation



Résumé

- Ablation :
 - 04:10 min de RF
 - 10kJ de RF
- Matériel :
 - Decanav (BIOSENSE)
 - STSF (BIOSENSE)